



# PATHOMORPHOLOGY OF THE FETAL ADRENAL GLANDS IN ACUTE AND CHRONIC HYPOXIA.

Mavlyan-Khojaeva A.R

Tashkent State Medical University

Department of Pathological Anatomy, Shifokorlar Street, 22, Tashkent, Uzbekistan

## Article history:

**Received:** November 26<sup>th</sup> 2025

**Accepted:** December 24<sup>th</sup> 2025

## Abstract:

One of the most important goals of the international public health system is the elimination of preventable infant and perinatal mortality (WHO, 2014) [1].

Key factors in the development of these changes include intrauterine fetal hypoxia and neonatal asphyxia, both acute and chronic. The adrenal gland is a key organ involved in the stress response. Despite this, data on the of the adrenal glands in acute and chronic hypoxia during the perinatal period remain incomplete and fragmented.

**Keywords:** adrenal glands, fetus, perinatal mortality, hypoxia, asphyxia, stress.

## 1. INTRODUCTION

Perinatal losses are one of the key factors characterizing the health of the population, its reproductive potential, and socioeconomic living conditions (Richardus JH et al., 1998 [2], Shrestha S. et al., 2010 [3]). The key to solving this problem is the diagnosis of its causes and mechanisms. According to various data, asphyxia and intrauterine hypoxia account for up to 43% and 67% of perinatal mortality cases, respectively (WHO, 2016 [4], Pal'tsev M.A. et al., 2002 [5]). In chronic intrauterine hypoxia, oxygen deficiency is usually moderate but persists for a long time, which allows the fetus to gradually adapt to changing living conditions. The fetus has compensatory mechanisms for transient hypoxia during labor, but prolonged, uninterrupted fetal hypoxia can lead to acidosis with cell death, tissue damage, organ failure, and possibly death. [6] The key difference in the development of acute and chronic asphyxia is the absence of a rapidly developing cascade of adaptive responses. Chronic hypoxia, which can be considered chronic stress, leads to the depletion of the body's compensatory resources (Braunstein H. et al., 1964) [7].

## 2. BACKGROUND

In the structure of perinatal mortality, the key factors in thanatogenesis are intrauterine fetal hypoxia and neonatal asphyxia in both acute and chronic forms. Clearly, acute perinatal hypoxia should be considered a state of critical adaptive changes, in which the adrenal gland plays a key role by synthesizing stress hormones - catecholamines and corticosteroids. Despite this, the literature describes morphological changes in the adrenal glands in the context of perinatal mortality in fragmented and sometimes contradictory ways. This underscores the need for an in-depth study of the patterns of morphological changes in the adrenal glands under the influence of various mechanisms of

thanatogenesis, with the aim of increasing the reliability of postmortem diagnostics.

## 3. OBJECTIVES

To study the impact of acute and chronic intrauterine hypoxia on the morphofunctional state of the adrenal cortex in fetuses.

## 4. METHODS

The material for the study was collected from autopsies performed at the Republican Pathological Anatomical Center of Uzbekistan in 2025. The sample included 35 fetuses with a gestational age of 24-40 weeks and a body weight of 500-4000g. The obtained material was distributed according to the presence or absence of chronic intrauterine hypoxia (CIP) (13 fetuses, gestational age  $30.3 \pm 5.9$  weeks) and acute hypoxia (12 fetuses, gestational age  $32.7 \pm 6.2$  weeks). The control group included fetuses from mothers with normal pregnancies and those with congenital malformations (10 fetuses, gestational age  $33.7 \pm 5.2$  weeks).

All obtained data were then divided into three groups: The first group included fetuses that had experienced acute hypoxia during a normal pregnancy (placental abruption, intrapartum asphyxia, aspiration syndrome). The adrenal glands of 16 fetuses with an average gestational age of  $32.7 \pm 6.2$  weeks were examined. Nine fetuses were female and seven were male.

Autopsies were performed within 10 hours of death. In all cases, the adrenal glands were removed from the fetuses, fixed in 10% formalin, and then embedded in paraffin blocks. The resulting sections were stained with hematoxylin and eosin. Microscopic examination of the specimens was performed using an Olympus BX-41 microscope. All obtained data were statistically processed using a licensed Microsoft Excel application package.

## 5. RESULTS

Macroscopic examination revealed that the adrenal glands in all groups were covered by a connective tissue capsule and had a pyramidal or crescentic shape. Adrenal size and weight correlated with gestational age. However, subcapsular hemorrhages were observed macroscopically in the chronic hypoxia group.

Microscopic examination revealed that in the group of fetuses that had experienced acute hypoxia but were not exposed to chronic hypoxia, such as in cases of intrapartum asphyxia, aspiration syndrome, or placental abruption, adrenal changes were less pronounced.

Subcapsular hemorrhages were observed in 40% of cases in this group. Other changes primarily affected the area adjacent to the central adrenomedullary vein.

In the acute hypoxia group, moderate vacuolization in the fetal zone adjacent to the central adrenal vein was observed in only six cases, and completely absent in six others. As mentioned previously, this histological pattern indicates degenerative changes, as these cells should not be vacuolated in a normal histological picture. In one of the six cases where moderate vacuolization was observed, small areas of hemorrhage were also detected in the fetal zone of the adrenal glands. Cirrhotic changes and delipidization in the

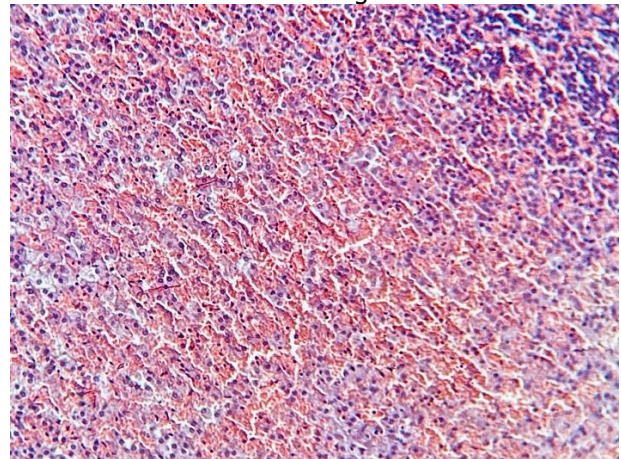
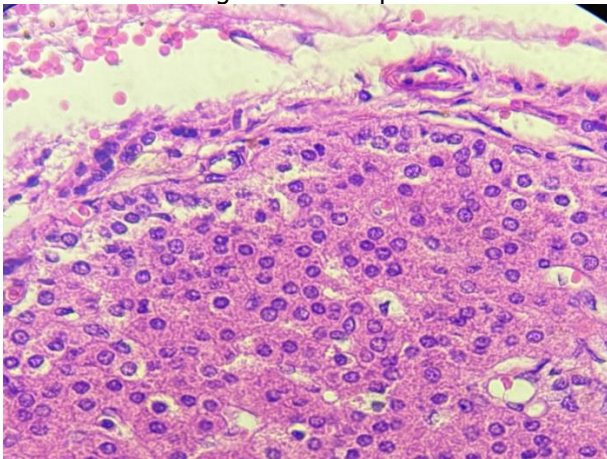
definitive adrenal cortex were also not detected in the acute perinatal hypoxia group.

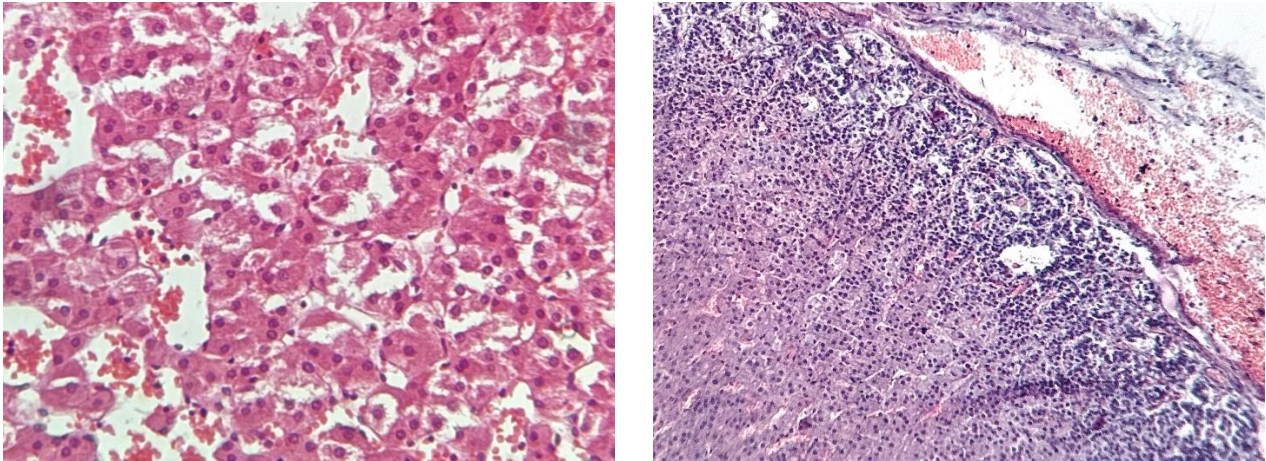
Microscopic examination of the adrenal glands revealed that in the second group (the chronic hypoxia group), changes affected virtually all layers of the adrenal glands.

Hemorrhages were observed in all cases studied. In 10 of these cases, hemorrhages were observed subcapsularly. Hemorrhages in the fetal zone were detected perivenularly in 1 case, and in deeper layers of the fetal zone in 6 cases. Hemorrhages were observed in all layers of the adrenal cortex in 5 cases.

In the chronic intrauterine hypoxia group, vacuolization of fetal cortex cells was observed in all cases. Moderate vacuolization was visualized in 3 of them. In the remaining 10 cases, pronounced vacuolization of the entire fetal cortex was observed. Moreover, areas of necrotic cells were detected in the fetal zone in 11 cases. In 8 of these cases, similar changes were also observed in the definitive cortex.

In addition to necrotic changes, delipidization was also visualized in the definitive cortex in 9 cases, indicating exhaustion of the adrenal glands as a stress response organ. Finally, in 8 cases, loose connective tissue (stroma) was observed at the site of necrotic areas in the form of cicatricial changes.





**Fig. 1. Morphological changes in the adrenal glands in acute and chronic fetal hypoxia.**

A. Normal vacuolation in the definitive zone of the adrenal glands. Subcapsular hemorrhage. Staining: hematoxylin and eosin. Original magnification x 400;

B. Hemorrhage in the fetal and definitive zones. Staining: hematoxylin and eosin. Original magnification x 200. (chronic fetal hypoxia group);

C. Chronic fetal hypoxia group. Hemorrhage in the fetal zone. Necrotic changes, pronounced vacuolation of individual cells. Staining: hematoxylin and eosin. Original magnification x 400 (chronic fetal hypoxia group);

D. Vacuolization of the fetal zone, delipidization of the definitive zone. Subcapsular hemorrhage, plethora of the sinuses of the fetal and definitive zones. Staining: hematoxylin and eosin. Original magnification x 100. (group of chronic fetal hypoxia).

## 6. DISCUSSION

Reducing the perinatal mortality rate is a priority not only for the healthcare system in Uzbekistan but also globally.

To achieve this goal, it is necessary to improve the postmortem diagnostic system to more clearly understand the immediate causes of fetal death. Furthermore, it is essential to understand the onset of the pathology leading to death.

Since acute and chronic fetal hypoxia are among the most common causes of perinatal death, with similar pathogenesis and morphological manifestations, but with different etiologies and onset during intrauterine development, their differential diagnosis is a crucial issue in pathological anatomy.

Thus, despite the absence of pronounced specific changes in the adrenal glands of fetuses with chronic and acute asphyxia, assessing the degree of these changes can not only serve as a reliable marker for differentiating between intrauterine and exceptional acute intranatal pathology but also indicate the onset of pathological changes. This is important not only for improving postmortem diagnosis of perinatal mortality cases, but also for enhancing understanding of the periods of greatest risk in the perinatal period, which is key to reducing perinatal morbidity and mortality.

## 7. CONCLUSIONS

1. The adrenal gland is a key marker for the differential diagnosis of chronic stress resulting from intrauterine pathology and solely intranatal pathology. Although the changes detected in acute and chronic hypoxia are not specific, the frequency and severity of their manifestations allow us to assess the nature of thanatogenesis. 2. Adrenal gland specimens from the group exposed to acute hypoxia revealed hemorrhages in the capsule and perivenular fetal zone of the adrenal glands, as well as moderate vacuolization in the fetal cortex.

3. Pathological examination of the adrenal glands from the group exposed to chronic hypoxia revealed sclerosis, hemorrhages in the capsule, fetal, and definitive zones of the adrenal glands, moderate to severe vacuolization of the fetal cortex, delipidization of the definitive cortex, and necrotic changes in all zones of the adrenal cortex.

## REFERENCES

1. Every newborn: an action plan to end preventable deaths. Geneva: World Health Organization; 2014. Available at: <http://apps.who.int/iris/bitstream/10665/127938/1/9789241507448eng.pdf>. Accessed July 26, 2016.



2. Richardus JH, Graafmans WC, Verloove-Vanhorick SP, Mackenbach JP. The perinatal mortality rate as an indicator of quality of care in international comparisons. *Med Care*. 1998 Jan;36(1):54-66. doi: 10.1097/00005650-199801000-00007. PMID: 9431331.
3. Shrestha S, Sharma A, Upadhyay S, Rijal P. Perinatal mortality audit. *Nepal Med Coll J*. 2010 Dec;12(4):257-9. PMID: 21744770.
4. International Statistical Classification of Diseases and Related Health Problems 10th revision. In: ICD version: 2016 [website]. Geneva: World Health Organization;
5. Пальцев М.А., Коваленко В. Л., Аничков Н.М. Руководство по биопсийно-секционному курсу: Учебное пособие . - М.: Медицина, 2002 . - 256 с. [Paltsev MA, Kovalenko VL, Anichkov NM. Rukovodstvo po biopsij-no-sekcionnomu kursu: Uchebnoe posobie. Moscow: Medicine; 2002. 256 p. (In Russ.)
6. Gravett C., Eckert L.O., Gravett M.G., Dudley D.J., Stringer E.M., Mujobu T.B. et al. Non-reassuring fetal status Working Group. Non-reassuring fetal status: Case definition & guidelines for data collection, analysis, and presentation of immunization safety data. *Vaccine*. 2016; 34(49): 6084-92. <https://dx.doi.org/10.1016/j.vaccine.2016.03.043>.
7. The human adrenal in rapid death and chronic illness. Braunstein H, Yamaguchi BT Jr. <https://www.ncbi.nlm.nih.gov/pmc/articles/PMC1907038/> *Am J Pathol*. 1964;44:113-126